

Runting and Stunting Syndrome (RSS)

Runting and Stunting Syndrome (RSS):

Malabsorption Syndrome (MAS) is basically an infectious disease that affects the intestinal tract of young fast growing broilers. It is characterized by retarded growth, feathering abnormality, immuno-depression, diarrhoea and high mortality with lesions in bursa, thymus and proventriculus, resulting in considerable economic losses especially in the commercial broiler industry.



Runting-stunting syndrome (RSS) was first reported in the 1940's, became well known to the commercial industry in the 1970's and has since been reported around the world.

Due to the absence of a known etiology, identification of the disease commonly relies on descriptive terms such as malabsorption syndrome, infectious stunting syndrome, broiler runting syndrome, and helicopter syndrome.



In poultry, an unusually small chick is referred as “runt” which means smallest of the flock, and retardation or hindering of normal growth comes under the term “stunting.” A condition in which members of a flock appear with relatively smaller bodies due to retarded growth is called runting stunting syndrome (RSS)





Etiology

However, through various studies, it has been proven that the following agents are involved:

1-Small, round, non-enveloped viruses have been suggested as the most probable etiologic agents based on electron microscopy.

Over the years, which included, Reovirus, rotavirus, parvovirus, entero like viruses and astrovirus have been detected or isolated from clinically affected chickens. These viruses have been demonstrated in intestinal contents or enterocytes isolated from birds with RSS. Although bacteria and environmental factors may be associated as contributors to the development of disease.

The nature of the inflammatory responses suggests a viral etiology rather than bacteria.

--**Certain strains of reovirus were originally implicated as the cause of RSS**, and vaccines have been developed for such strains.

2. Mycotoxins such as fusarium.

3. High stocking density and poor hygiene.

A problem hampering the understanding of the etiology is the inability to isolate these viruses. Because the disease is seen in very young chicks, it is likely the viruses are vertically transmitted, although fecal/oral spread occurs after hatching. The involvement of feed borne mycotoxins is not well understood.

Clinical Findings

1-The first clinical signs may be observed as early as 3 days of age but are most commonly seen in 6 to 12 day-old chicks and may last up to 3 weeks of age.

2-It is characterized by retarded growth; temporary stunting; permanent runting.

3-Birds may huddle together in the drier parts of the poultry house to keep themselves warm. This condition may be more prevalent during winter and early spring.

4-Lack of pigmentation in the skin, feet, or beak

4-Slow feathering; broken or twisted feathers (“helicopter wings”)

5-Undigested feed in the feces; and poor feed conversion ratios.

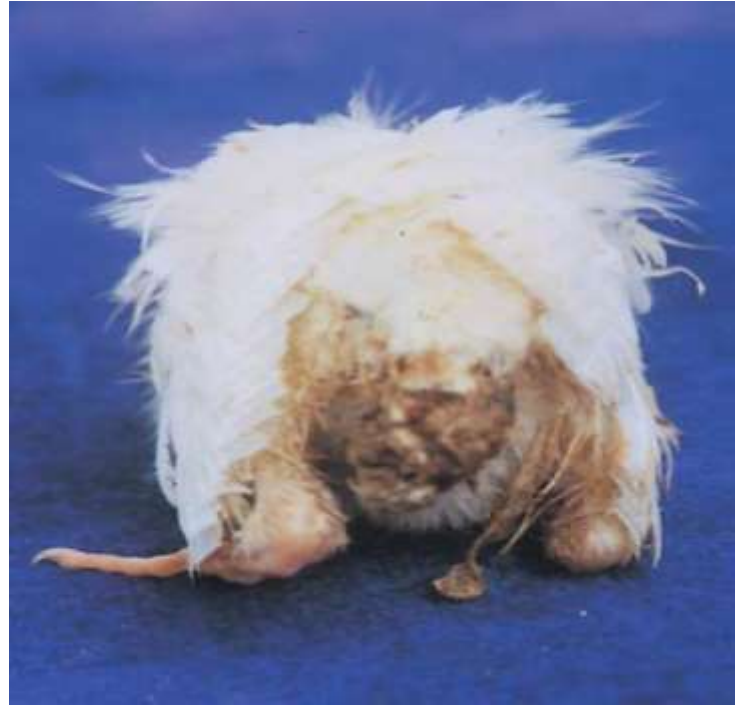6-Diarrhea is common during the initial phases, and eating feces is seen.

7-Other signs include lameness, osteodystrophy, and secondary encephalomalacia. Severely affected birds do not respond immediately to changes in feed or management practices and are usually culled from flocks before processing.

8- The number affected birds in the flock can vary from a few to 90%.

9-Mortality and aggressive culling may reach up to 60% and feed conversion may be decreased 20 points with the consequent economic losses.

10-The legs and beak of affected birds may appear pale in color (pale bird syndrome) and some birds may have rickets or broken legs.

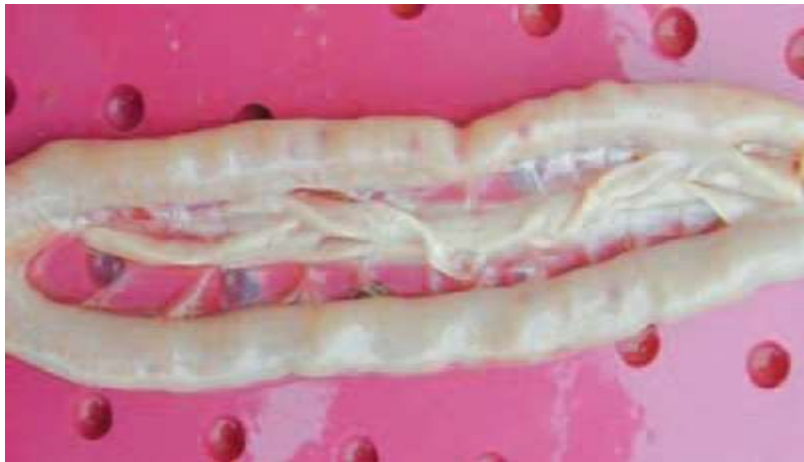

Gross lesions

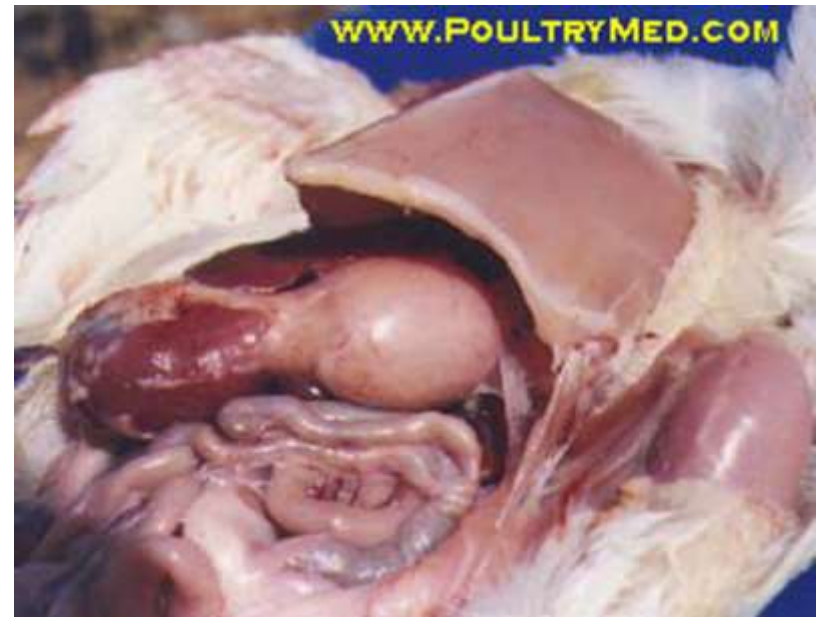
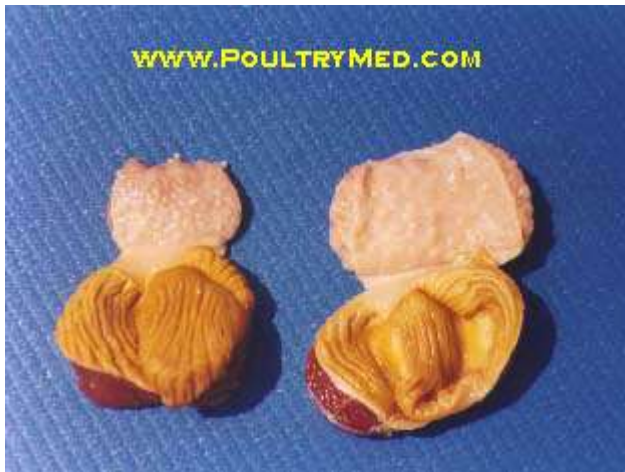1-In natural outbreaks, early pathological changes were observed in crypts of Lieberkuhn in most of the cases of 1st week. These changes include the cystic dilation, necrosis and degeneration of epithelial lining, accumulation of cellular debris and sometimes loss of crypts, while pancreatic atrophy has first been reported on 11th day.

- Pancreases from diseased birds degenerate and digestive enzymes are reduced.

-The livers are generally small, but gall bladders are enlarged.

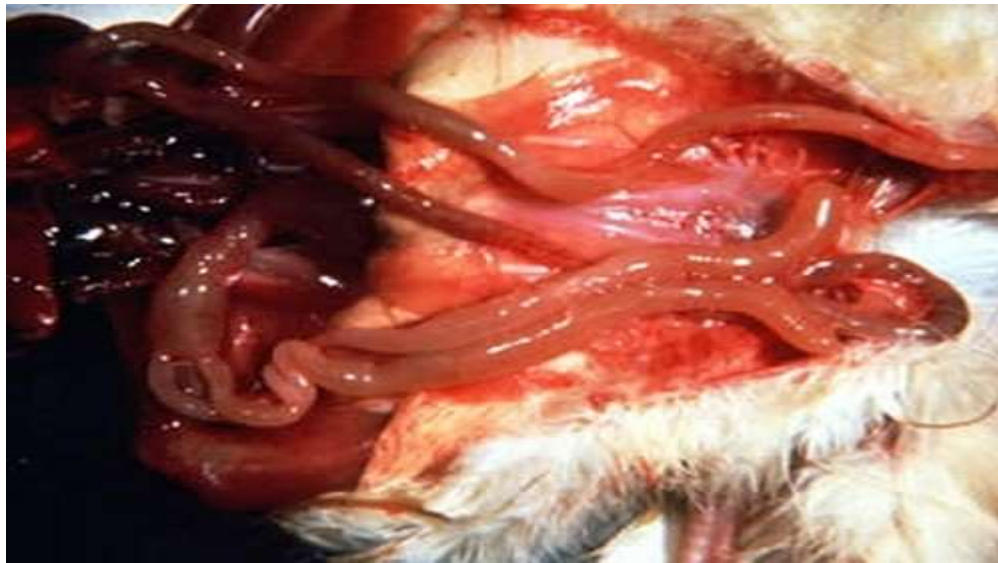

- 2-RSS birds show a pale carcass and shanks, wasted breast muscles.
- 3-The thymus and bursa small in size and Lesions often include enlarged proventriculus, small gizzards, pancreatic atrophy.
- 4-The walls of the proventriculus are thickened and the lining shows areas of inflammation and haemorrhages around the opening of the mucus glands.



5-Enlargement of intestine with thin-walled filled with fluid as a result of malabsorption syndrome. The intestine fill with water and undigested feed particles. In a recent case of RSS.

6-Pale small intestines with transparent walls and ballooning due to gas accumulation. Gross lesions in the duodenum are usually mild. The jejunum and ileum are most affected but the ceca may also be gaseous and distended.



Diagnosis

Clinical signs and postmortem lesions permit a presumptive diagnosis.

Because of the complex etiology and the presence of enteric viruses in normal flocks, laboratory investigations may be difficult to interpret, particularly because virus culture may be difficult or impossible.

Poor early management of flocks (especially feed and water supply and temperature control) may lead to a similar picture in the absence of specific infection.

Prevention and Control

1-To control RSS we have to look at various measures. Most of all at proper cleaning and disinfection of affected premises.

2-There is no effective treatment for severely affected birds.

3-Good broiler farm hygiene will reduce the burden of challenge caused by multiple infectious organisms.

4-Good flock nutrition and sanitation and avoidance of intercurrent disease are beneficial.

5-No vaccines prevent malabsorption syndrome.

Some reovirus vaccines are marketed to prevent the stunting and poor feed conversions due to pathogenic reoviruses.

6-Feeds should be analyzed for dietary toxins, and high levels of toxins should not knowingly be fed to commercial poultry.

7-Antibiotics and vitamin supplements can be helpful.

Prevention and Control

8-When preparing the feed one should consider an increase of the minimum required level of methionine and lysine in order to prevent deficiency.

9-One should increase the supplemental vitamin E level to 100 ppm, while carotenoids may be used to supply additional vitamin A activity.

10-Do not forget to feed maximum levels of selenium, according local regulations, as it aids in reduction of mortality due to encephalomalacia.